

# Transepithelial corneal crosslinking for keratoconus



Peter S. Hersh, MD, Michael J. Lai, BS, John D. Gelles, OD, Sebastian P. Lesniak, MD

**Purpose:** To evaluate outcomes of corneal crosslinking (CXL) using a transepithelial technique for the treatment of keratoconus.

**Setting:** Cornea and refractive surgery subspecialty practice.

**Design:** Prospective case series.

**Methods:** Transepithelial CXL was performed in keratoconic eyes using riboflavin 0.1% and topical anesthetic containing benzalkonium chloride to facilitate riboflavin diffusion through the epithelium. Eyes were randomized to receive riboflavin administration either every 1 minute or every 2 minutes during ultraviolet-A exposure at 3mW/cm<sup>2</sup>. The principal outcome was change in maximum keratometry (K) and secondary outcomes included uncorrected (UDVA) and corrected (CDVA) distance visual acuities, mean K, and comparison of randomized groups.

**Results:** Eighty-two eyes of 56 patients were treated. At 1 year, maximum K decreased significantly by 0.45 diopters (D)  $\pm$  1.94

(SD); it improved by 2.0 D or more in 11 eyes (13%) and worsened by 2.0 D or more in 4 eyes (5%). The mean UDVA significantly improved by 0.7 lines, whereas the CDVA improved by 0.2 lines. Two eyes showed both continued progression with loss of CDVA. Only the 1-minute subgroup showed significant improvements in maximum K (-0.73 D) and UDVA. Transient corneal erosion and epitheliopathy were reported in 21% of eyes.

**Conclusions:** Transepithelial CXL resulted in significant improvements in maximum K and UDVA over 1 year. There was a suggestion that increased riboflavin dosing might improve procedure outcomes. Further study is required to determine the relative advantages and disadvantages of different transepithelial approaches to the standard CXL protocol with epithelial removal.

*J Cataract Refract Surg* 2018; 44:313–322 © 2018 ASCRS and ESCRS

Corneal crosslinking (CXL) is a promising procedure to treat keratoconus that has been shown to stop or slow the disease's progression.<sup>1</sup> Moreover, CXL might decrease the steepness of the cone and improve visual acuity and subjective visual function in some cases.<sup>2–9</sup> To date, most studies of CXL have assessed a standard technique in which the central corneal epithelium is first removed. This is the technique that has been approved for the treatment of progressive keratoconus in the United States.<sup>10</sup> In transepithelial CXL, the corneal epithelium is retained. This offers possible clinical advantages; the lack of an epithelial defect might facilitate faster recovery with decreased discomfort and might reduce the risk for infection.

In our previously published study,<sup>11</sup> the results of transepithelial CXL appeared encouraging; general improvement in topographic maximum keratometry (K) and

corrected distance visual acuity (CDVA) were found at 6 months postoperatively. This paper reports 1-year results to evaluate the safety and efficacy of transepithelial CXL to treat keratoconus. In addition, we evaluated 2 riboflavin-dosing regimens to ascertain any differences in safety and efficacy outcomes.

## PATIENTS AND METHODS

Patients with keratoconus were enrolled as part of a prospective randomized controlled clinical trial ([ClinicalTrials.gov NCT01464268<sup>A</sup>](https://clinicaltrials.gov/ct2/show/study/NCT01464268)) performed under a physician-sponsored Investigational New Drug. An investigational review board approved and monitored the study. The study was compliant with the U.S. Health Insurance Portability and Accountability Act, and it adhered to the tenets of the Declaration of Helsinki. Informed consent was obtained from each patient before any required study procedures were performed.

Inclusion criteria included a diagnosis of keratoconus, age 14 years or older, CDVA worse than 20/20, central or inferior

Submitted: June 9, 2017 | Final revision submitted: November 17, 2017 | Accepted: December 10, 2017

From the Cornea and Laser Eye Institute–Hersh Vision Group (Hersh), CLEI Center for Keratoconus (Hersh, Lai, Gelles), Teaneck, and the Department of Ophthalmology, Rutgers–New Jersey Medical School (Hersh, Lesniak), Newark, New Jersey, USA.

Supported in part by an unrestricted grant to the Department of Ophthalmology, Rutgers–New Jersey Medical School, Newark, New Jersey, from Research to Prevent Blindness, Inc., New York, New York, USA. The investigational product was provided by Peschke Trade GmbH, Huenenberg, Switzerland; they played no role in study design, data collection, data analysis, manuscript preparation, or the decision to submit the report for publication.

Corresponding author: Peter S. Hersh, MD, Cornea and Laser Eye Institute–Hersh Vision Group, CLEI Center for Keratoconus, 300 Frank Burr Boulevard, Suite 71, Teaneck, New Jersey 07666, USA. E-mail: [phersh@vision-institute.com](mailto:phersh@vision-institute.com).

steepening on a rotating Scheimpflug camera map (Pentacam, Oculus Optikgeräte GmbH), and Placido disk topography consistent with keratoconus.

Exclusion criteria included corneal thickness less than 350  $\mu\text{m}$  at the thinnest point measured by Scheimpflug analysis in the eye to be treated; previous ocular condition that might predispose the eye to complications (eg, recurrent erosion syndrome, corneal melt, corneal dystrophy, herpes simplex, herpes zoster keratitis); clinically significant corneal scarring; history of chemical injury or delayed epithelial healing; a known sensitivity to study medications; nystagmus or any other condition that would prevent a steady gaze during the CXL treatment or other diagnostic tests; and a current condition that, in the investigator's opinion, would interfere with or prolong epithelial healing. Patients who were pregnant or lactating were also excluded.

Contact lens wearers were instructed to discontinue spherical soft lenses for a minimum of 3 days and soft toric and rigid-gas permeable lenses for a minimum of 2 weeks before the preoperative eye examination. Stability was determined by comparing maximum K measurements between 2 visits at least 1 week apart and ascertaining that they did not differ by more than 0.75 diopters (D).

Each patient was randomized to administration of riboflavin every 1 minute or every 2 minutes for the duration of ultraviolet-A (UVA) exposure. Randomization was computer generated at the initiation of the trial and placed in a numbered sequence of envelopes. On the procedure day, the sealed randomization envelope was opened by the investigator. Patients and investigators were aware of the randomly assigned group.

### Surgical Technique

To enhance permeability of the epithelium to riboflavin, patients initially received proparacaine containing benzalkonium chloride (BAC) 0.01% (Bausch & Lomb, Inc.) every 5 minutes for 30 minutes. Subsequently, riboflavin 0.10% in sterile water (Peschke GmbH) was administered every 2 minutes. In patients enrolled early in the study, riboflavin was first administered for 30 minutes. In patients with poor penetration, an 8.0 mm cellulose sponge pledget soaked in riboflavin was then placed on the cornea for 15 minutes with continued administration of riboflavin every 2 minutes. Because of the enhanced efficacy of riboflavin penetration using this technique, application of the pledget was made standard in later cases. In all cases, the pledget was removed after 15 minutes and riboflavin dosing was continued until the investigator verified complete diffusion of riboflavin throughout the corneal stroma on slitlamp examination.

Ultraviolet-A 365 nm light (UV-X system, IROC Innocross AG) was then administered for 30 minutes at an irradiance of 3.0  $\text{mW}/\text{cm}^2$  for a total dose of 5.4 J. Riboflavin drops were continued during the UVA treatment per randomization; in the 2-minute subgroup, riboflavin was applied to the cornea every 2 minutes, in the 1-minute subgroup, riboflavin was applied to the cornea every 1 minute. In both subgroups, proparacaine-BAC 0.01% was administered every 10 minutes for the duration of the UVA exposure. After the treatment, topical antibiotic and prednisolone acetate 1.0% drops were administered. A therapeutic bandage contact lens (Acuvue Oasis, Johnson & Johnson) was then applied. Postoperatively, patients were prescribed an antibiotic 4 times daily for 7 days, prednisolone acetate 1.0% 4 times a day for 2 weeks, and preservative-free artificial tears as needed.

### Patient Assessment

Patients had complete examinations at baseline, on the day of treatment, and at 1 day, 1 week, and 1, 3, 6, and 12 months after treatment. Patients were instructed to leave contact lenses out for at least 1 week before examinations. Outcomes were analyzed for all eyes with data at 12 months, and also for a consistent cohort (having data at all timepoints) at 1, 3, 6, and 12 months.

### Outcome Measures

**Maximum Keratometry** The point of maximum K value was obtained preoperatively and 1 year postoperatively using a rotating Scheimpflug camera. Maximum K was chosen as the primary efficacy outcome since it is an objective quantitative endpoint and because it measures a salient feature of keratoconus, that is, the steepness of keratoconic topography distortion. Since keratoconus tends to be a progressive disease,<sup>12</sup> change in maximum K was used as a proxy for disease progression, regression, or stabilization. The mean K as derived from the Scheimpflug instrument was also analyzed.

**Visual Acuity** The uncorrected distance visual acuity (UDVA) and CDVA were obtained preoperatively and postoperatively at 1 year. Visual acuity measurements were taken under controlled lighting conditions using a modified Lighthouse Early Treatment Diabetic Retinopathy Study visual acuity test (2nd edition) with Sloan letters. Patients were tested 4 m from the visual acuity chart. If patients could not read any letters at 4 m, they were tested at 2 m. Visual acuity was recorded and analyzed as the logarithm of the minimum angle of resolution (logMAR) value. The CDVA was measured by manifest subjective refraction.

### Statistical Analysis

The primary efficacy outcome of the study was change in maximum K over 1 year after CXL in the entire population. Three groups were analyzed as follows: all eyes with preoperative and 1-year postoperative data in the entire cohort, the 2-minute subgroup, and the 1-minute subgroup. To define the clinical time course of outcome changes, a consistent cohort of all eyes treated (eyes having data for all visits) was also analyzed. To compare the postoperative outcomes with the baseline values, a paired Student *t* test was used. A 2-sample *t* test was used to compare baseline data and outcomes data 1 year postoperatively between the 2-minute subgroup and the 1-minute subgroup. A *P* value less than 0.05 was considered statistically significant.

## RESULTS

### Study Characteristics

Eighty-two eyes of 56 patients with keratoconus (44 men, 12 women) had transepithelial CXL and were followed for 12 months. The average age of the patients was 31.4 years (range 18 to 60 years). There were 44 eyes in the 1-minute subgroup and 38 eyes in the 2-minute subgroup. Of the 82 eyes in the entire cohort, 66 eyes had data at all timepoints. This consistent cohort included 66 eyes from 44 patients (36 men, 8 women), with 37 eyes in the 1-minute subgroup and 29 eyes in the 2-minute subgroup. Ten eyes (12%) required riboflavin dosing for more than 60 minutes; the longest required to achieve penetration was 80 minutes.

### Corneal Topography

**Maximum Keratometry** There was a statistically significant flattening in the mean maximum K value ( $P = .04$ ) from preoperatively to 1 year (Table 1). Looking at individual eyes, the maximum K decreased by 2.00 D or more in 11 eyes (13.4%) and increased by 2.00 D or more in 4 eyes (4.9%) (Figure 1).

**Clinical Time Course of Topography Change** Figure 2 shows the changes over time in maximum K in the consistent cohort. Maximum K was generally stable for the first month and improved at 3 months. This consistent cohort confirms

**Table 1. Scheimpflug topographic keratometry.**

Parameter/Group	Mean ± SD		Mean Change	P Value		
	Preop	12 Mo Postop		P Value	Preop Difference (1 vs 2 min cohort)	Change (1 vs 2 min cohort)
Maximum K (D)					.03*	.16
All Eyes (N = 82)	57.00 ± 8.11	56.55 ± 7.91	-0.45	.04†		
1 min (n = 44)	55.15 ± 7.8	54.42 ± 6.98	-0.73	.03†		
2 min (n = 38)	59.16 ± 8.03	59.02 ± 8.28	-0.14	.61		
Mean K (D)					.14	.65
All Eyes (N = 82)	47.92 ± 5.22	47.90 ± 4.87	-0.02	.88		
1 min (n = 44)	47.13 ± 4.85	47.06 ± 4.35	-0.07	.64		
2 min (n = 38)	48.84 ± 5.55	48.88 ± 5.29	0.04	.83		

K = Keratometry

\*Significant difference between the 1-minute and 2-minute subgroups

†Significant change comparing 12 months postop to baseline value within groups

a statistically significant improvement in maximum K over 1 year (-0.66 D, *P* = .01).

**Mean Keratometry** There was no change in mean K from preoperatively to 1 year (Table 1). The mean K decreased by 2.00 D or more in 4 eyes (4.9%) and increased by 2.00 D or more in 2 eyes (2.4%).

**Subgroup Comparison** There was a statistically significant difference between the baseline maximum K of the 1-minute and 2-minute administration subgroups (55.2 versus 59.2 D, *P* = .025) (Table 1). There was no statistically significant difference in mean K between the 2 subgroups either preoperatively or postoperatively. When analyzing each subgroup individually, only the 1-minute group showed a statistically significant improvement in maximum K (*P* = .03) compared with the 2-minute administration group. However, in a direct statistical comparison between the subgroups, there were no significant differences in the 1-year changes in maximum K or mean K.

**Visual Acuity**

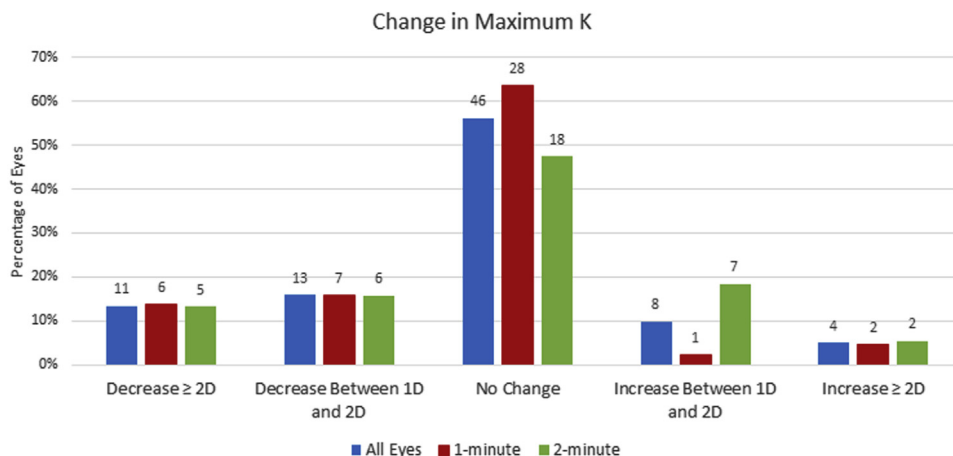
**Uncorrected Distance Visual Acuity** Table 2 shows the changes in UDVA between baseline and 12 months postoperatively. The UDVA improved significantly by somewhat more than a half line from preoperatively to 12 months postoperatively (*P* = .02). The UDVA improved by 2 or more lines in

32.9% of the eyes, whereas 13.4% of the eyes lost 2 or more lines of UDVA (Figure 3).

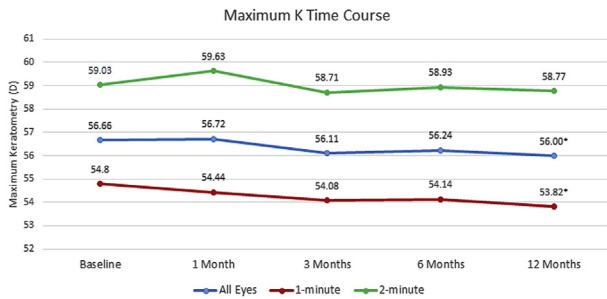
**Time Course of Uncorrected Distance Visual Acuity** Figure 4 shows the changes in UDVA over time in the consistent cohort. Postoperatively, the UDVA improved at 1 to 3 months with stabilization thereafter. The consistent cohort confirms a statistically significant improvement in the UDVA over 1 year (-0.06 logMAR, *P* = .04).

**Corrected Distance Visual Acuity** Table 2 shows the changes in the CDVA between baseline and 12 months postoperatively of the entire cohort. There was no significant change in the CDVA from preoperatively to 1 year postoperatively (*P* = .43). The CDVA improved by 2 or more Snellen lines in 20.7% of the eyes, whereas 13.4% of the eyes lost 2 or more Snellen lines of CDVA (Figure 5).

**Subgroup Comparison** There were no statistically significant differences in baseline UDVA or CDVA between the 2 subgroups (Table 2). When analyzing each subgroup individually, neither showed a significant change in the CDVA. Analyzing the UDVA change, only the 1-minute group showed a statistically significant improvement (1-line improvement, *P* = .02), compared with a 0.3 line improvement in the 2-minute administration group.



**Figure 1.** Change in maximum K (D) for individual eyes at 1 year. The number of eyes are noted above the columns (K = keratometry).



**Figure 2.** Change in maximum K (D) over time (consistent cohort, n = 66) (\* = significant change comparing 12 months postoperative with the baseline value within groups; K = keratometry).

However, in a direct statistical comparison between the subgroups, there were no significant differences in the 1-year changes in either UDVA or CDVA.

### Epithelial Healing

All patients received a therapeutic soft contact lens after surgery. In 47 eyes (57%), the lens was removed on the first postoperative day. The bandage soft contact lens was kept in place for 2 to 7 days in 35 eyes (42%), typically for residual epitheliopathy or subjective discomfort.

Ten eyes (12%) had epithelial erosions; 3 were noted immediately after the procedure and 7 were seen on the first postoperative day. All of these resolved with use of a bandage contact lens. In addition, 7 eyes (9%) showed a discrete area of punctate keratopathy on the first postoperative day. Thus, 17 eyes (21%) in toto showed epitheliopathy after the procedure. Of the 10 eyes with

epithelial defects, 4 had mild stromal haze at 3 months and 2 had remaining haze at the 12-month examination; no decrease in the CDVA was seen in these eyes. One eye with an epithelial defect showed a 1-year loss in CDVA (20/20<sup>-</sup> to 20/32<sup>+</sup>), but no haze or scarring; disease progression was noted in this eye.

### DISCUSSION

Transepithelial CXL has been suggested as an alternative to the standard CXL procedure (in which the epithelium is initially debrided). Putative advantages include faster healing, improved patient comfort, and less risk for corneal haze or infectious keratitis.<sup>13-16</sup> In addition, this technique might decrease corneal thinning during the CXL procedure and allow treatment of more severe cases in which corneal thickness might otherwise preclude treatment.<sup>17</sup>

This single center randomized controlled clinical trial is 1 of the largest to date designed to analyze safety and efficacy outcomes of transepithelial CXL. In addition, 2 dosing regimens (every 1-minute or 2-minute riboflavin administration during UVA treatment) were compared to determine advantages or disadvantages to procedure outcomes.

Although of potential clinical advantage, there are several theoretical and practical hurdles to transepithelial CXL being as effective in mitigating keratoconic progression as standard CXL. First, the epithelium itself is a barrier to diffusion of riboflavin, a large molecule, into the corneal stroma. There are evolving methods, however, to enhance diffusion, such as those we have used in this study. These include eliminating dextran from the riboflavin carrier, treating with adjunctive BAC containing solutions or other

**Table 2. Visual acuity.**

Visual Acuity/Cohort	Preop	12 Mo Postop	Mean Change	P Value		
				P Value	Preop Difference (1 vs 2 min cohort)	Change, (1 vs 2 min cohort)
UDVA					.08	.21
All eyes (N = 82)						
Mean logMAR ± SD	0.77 ± 0.42	0.70 ± 0.37	-0.07	.02*		
Snellen equivalent	20/118	20/100				
1 min (n = 44)						
Mean logMAR ± SD	0.85 ± 0.42	0.75 ± 0.39	-0.10	.02*		
Snellen equivalent	20/142	20/112				
2 min (n = 38)						
Mean logMAR ± SD	0.68 ± 0.41	0.65 ± 0.35	-0.03	.34		
Snellen equivalent	20/96	20/89				
CDVA					.49	.51
All eyes (N = 82)						
Mean logMAR ± SD	0.26 ± 0.22	0.24 ± 0.20	-0.02	.43		
Snellen equivalent	20/36	20/35				
1 min (n = 44)						
Mean logMAR ± SD	0.25 ± 0.21	0.22 ± 0.19	-0.03	.28		
Snellen equivalent	20/36	20/33				
2 min (n = 38)						
Mean logMAR ± SD	0.28 ± 0.23	0.27 ± 0.20	-0.01	.85		
Snellen equivalent	20/38	20/37				

CDVA = corrected distance visual acuity; logMAR = logarithm of the minimum angle of resolution; UDVA = uncorrected distance visual acuity

\*Significant change comparing 12 months postop to baseline value within groups

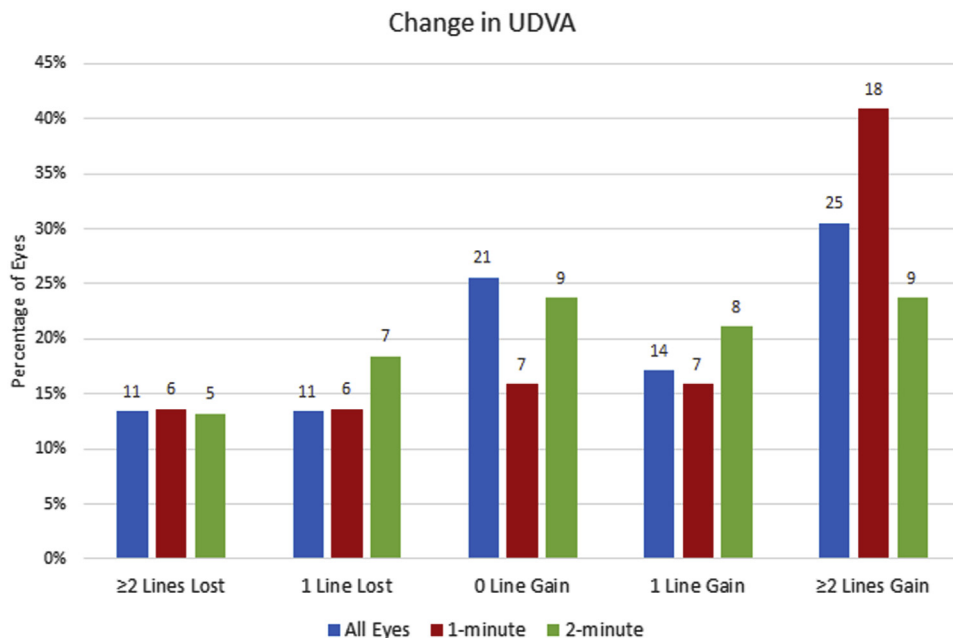


Figure 3. Change in UDVA (Snellen lines) for individual eyes at 1 year. The number of eyes are noted above the columns (UDVA = uncorrected distance visual acuity).

permeability enhancers, and improving contact of the riboflavin with the cornea by means of a soaked pledget.

To date, dextran has been included in most riboflavin formulations that are used clinically, based on its documented efficacy in the standard CXL procedure with the epithelium removed.<sup>10</sup> However, inclusion of dextran in the riboflavin solution substantially diminishes its ability to penetrate the epithelium. In a study of rabbit eyes using riboflavin in a dextran solution,<sup>13</sup> transepithelial CXL was less effective than standard CXL. In other laboratory research using riboflavin in a dextran solution,<sup>15,18</sup> stromal concentrations of riboflavin failed to reach levels sufficient for effective crosslinking. In contrast, riboflavin in solutions without dextran seem to facilitate penetration through the epithelium.<sup>19,20</sup> In further efforts to improve the epithelial permeability to riboflavin diffusion, adjunctive agents such as BAC have been shown to be advantageous.<sup>21–24</sup> Similarly, ethylenediaminetetraacetic acid (EDTA) can increase permeability to hydrophilic molecules such as riboflavin.<sup>25,26</sup> New methods to facilitate riboflavin uptake such as iontophoresis are also being developed.<sup>27,28</sup>

Notwithstanding adequate stromal absorption of riboflavin, other factors might mitigate the crosslinking effect in the setting of an intact epithelium. First, both the surface riboflavin film<sup>29</sup> and the riboflavin-soaked epithelial layer might absorb incident UVA light, attenuating the UV power/stromal depth relationship. Consequently, this might decrease the depth at which the threshold power for a crosslinking effect is met and the actual crosslinking would be less deep and robust than with the epithelium absent. Supporting this thesis is evidence that cytotoxic keratocyte damage is restricted to a more anterior, approximately 200 μm, stromal depth in the transepithelial CXL approach.<sup>13,14</sup> To diminish attenuation of UV power by surface riboflavin and riboflavin-soaked epithelium, it has been suggested that the riboflavin within the epithelial layer be removed before UV exposure by rinsing the corneal surface, and then suspending further riboflavin administration during the UV administration.<sup>30</sup> Although this was not specifically evaluated in our investigation, the potential advantage of this technique is belied by our findings of more robust improvements in maximum K and UDVA in the every 1-minute compared with the 2-minute riboflavin administration randomized subgroup; that is, there was a trend toward better outcomes with greater, not lesser, administration of riboflavin during UV exposure.

In addition to the UV barrier effect, the epithelium might diminish oxygen diffusion into the corneal stroma, further attenuating the crosslinking effect by limiting the crosslinking reactions that occur through oxygen-dependent pathways.<sup>31</sup> Investigators are studying the effects of pulsed-light protocols to allow greater oxygen diffusion as well as oxygen supplementation as modalities to enhance crosslinking in transepithelial procedures.<sup>32</sup>

Finally, as noted in our previous work on standard CXL,<sup>2</sup> the role of wound healing in the ultimate clinical effect of the procedure is unclear. After the standard CXL procedure,

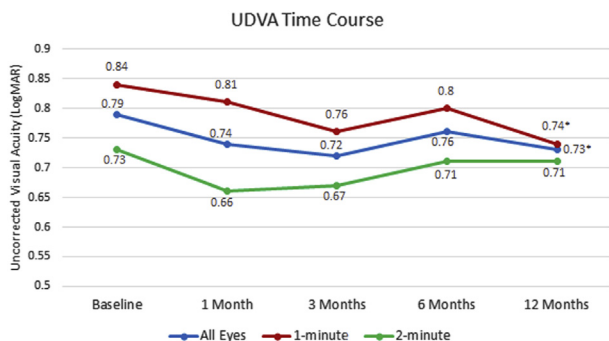
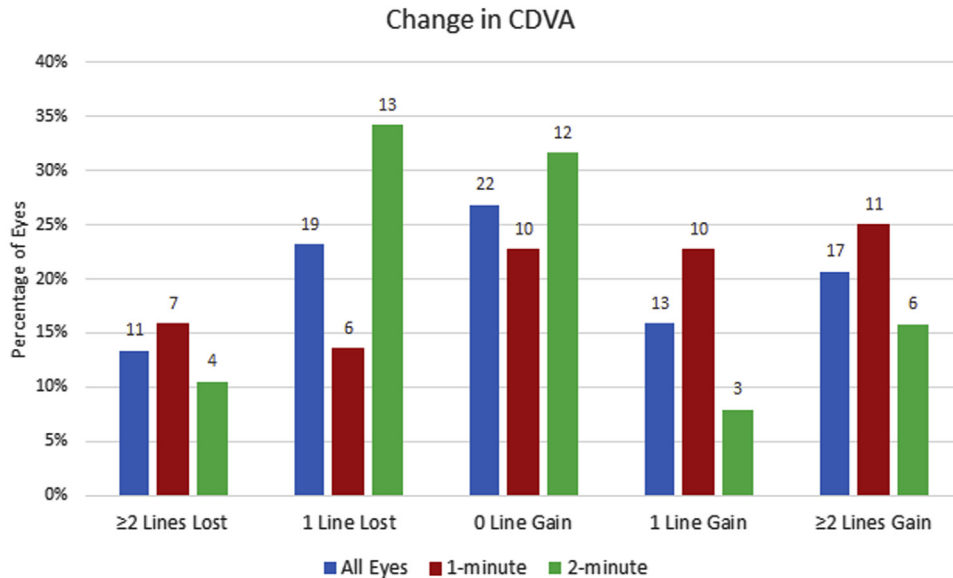


Figure 4. Change in UDVA over time (consistent cohort) (\* = significant change comparing 12 months postoperative with the baseline value within groups; logMAR = logarithm of the minimum angle of resolution; UDVA = uncorrected distance visual acuity).



**Figure 5.** Change in CDVA for individual eyes at 1 year (Snellen lines). The number of eyes are noted above the columns (CDVA = uncorrected distance visual acuity).

there is a typical corneal stromal haze and demarcation line that follows a generally consistent time course; haze appears and is maximum at 1 month through 3 months and diminishes to baseline over the course of a year.<sup>16</sup> Indeed, haze appears to be a normal concomitant of the standard CXL procedure and is first observed as dust-like change in the anterior corneal stroma which evolves into a mid-stromal demarcation line.<sup>33</sup> Crosslinking-associated corneal haze is most likely a measure of back-scattered and reflected light, causing decreased corneal transparency, and likely demarcates the depth of the actual CXL effect.<sup>34</sup> This might be an effect of biologic changes such as keratocyte apoptosis, keratocyte repopulation, and changes within the collagen fibrils and surrounding glycosaminoglycans. Such haze is not seen, generally, in the transepithelial procedure, a finding touted as an advantage of the latter. However, whether stromal haze is an unwanted side effect of CXL or, rather, is a proxy for beneficial stromal healing that might enhance a clinically effective crosslinking effect is unclear.

#### Literature on Transepithelial Crosslinking

Published results of transepithelial CXL efficacy have shown both positive and negative results of the procedure. They are difficult to compare because they are not uniform in design; different riboflavin formulations and adjunctive agents have been reported, different dosing regimens have been used, and varied techniques have been promulgated. For instance, Caporossi et al.,<sup>25</sup> using riboflavin and dextran with EDTA and trometamol as permeability enhancers, reported initial improvement in vision after transepithelial CXL, but a subsequent worsening of the maximum K value at 24 months. Gatziofufas et al.<sup>35</sup> used riboflavin in a 0.01% BAC-containing solution and a 10-minute exposure to 9 mW/cm<sup>2</sup> and reported progression in 46% of eyes. Koppen et al.,<sup>36</sup> using riboflavin containing dextran and BAC, found improvement in CDVA but worsening of the maximum K. Showing more positive results, Filippello et al.<sup>26</sup> found general topography improvement after transepithelial CXL using riboflavin and dextran, EDTA,

and trometamol. In another study, Stojanovic et al.<sup>20</sup> reported improvement in the UDVA, CDVA, and maximum K value after transepithelial CXL aided by superficial mechanical disruption of the epithelium. In a pediatric population, Salman<sup>37</sup> found improvement in UDVA and maximum K value; he used riboflavin and dextran with EDTA, BAC, and trometamol. Leccisotti and Islam,<sup>38</sup> using riboflavin and dextran and gentamicin, BAC, and EDTA, reported an improvement in the CDVA and mean K value. Rechichi et al.<sup>39</sup> used a corneal disruptor device to improve riboflavin diffusion and found a statistically significant improvement in UDVA and CDVA, and improvement in the mean simulated K value and steepest simulated K value over 12 months.

#### Study Results

In our study, we used riboflavin 0.1% solution without dextran and adjunctive administration of proparacaine with BAC to increase the permeability of the epithelium. In addition, we found that the application of an 8.0 mm pledget soaked in riboflavin for 15 minutes improved riboflavin uptake, likely a result of enhanced contact as well as mild trauma to the epithelium. Although most eyes achieved saturation in 1 hour, some required up to 80 minutes for complete saturation.

We used the maximum K value on corneal topography as our primary efficacy outcome. Maximum K was chosen because it measures a salient feature of keratoconus; that is, the steepness of keratoconic topographic distortion. Moreover, topographic maximum K affords an objective quantitative endpoint. Overall, maximum K decreased by a mean of 0.45 D over 1 year, a clinically modest but statistically significant finding. Looking at individual eyes, most eyes remained stable whereas 13% improved by 2 or more diopters and 5% increased by 2 or more diopters; 15% increased by 1 or more diopters. Although, these latter eyes might be considered treatment failures because cone progression was not stabilized, it is unclear what the natural evolution of the disease might have otherwise revealed; it is

possible that disease progression was slowed but not completely, or that progression, indeed, proceeded apace.

In addition to the primary efficacy measurement of maximum K, changes in CDVA might point to additional efficacy or, conversely, to safety concerns after CXL. In this study, there was no change in mean CDVA over 1 year. Given the general improvement in maximum K and improvement in UDVA, we might have expected improvement in CDVA as well. However, the topography improvement, although significant, was modest and, thus, might not manifest a clinically significant effect on corrected vision. Among patients receiving CXL, 20 eyes (24%) gained 2 or more lines of CDVA, whereas 11 eyes (13%) lost 2 lines or more. Curiously, of the 11 eyes with CDVA loss, maximum K was stable in 7, improved by 2.0 D or more in 2 eyes, and steepened by 2.0 D or more in only 2 eyes. Thus, there was no obvious association of loss in CDVA with continued topographic progression. If we use the combined outcomes of continued worsening of maximum K associated with loss of CDVA, 2 eyes (2.4%) in the study can be considered to have suffered advancing disease even after the CXL procedure. Retreatment was suggested for these 2 patients; however, they deferred and were lost to subsequent follow-up.

Of clinical note, this technique was typically associated with substantial punctate keratopathy of the epithelium after the procedure, and with frank epithelial erosion in 10 eyes. Because the native corneal epithelium acts as a barrier to diffusion of a large molecule such as riboflavin, the essential challenge of transepithelial CXL is to chemically or mechanically effect a microtrauma to the epithelium to enhance its permeability. Thus, it is likely that the lengthy time of riboflavin administration, chemical manipulation with BAC, and the minor trauma secondary to plectet application leads to transient epitheliopathy or even frank epithelial erosion in a number of cases. Although patient subjective pain was not prospectively assessed, 29 patients (35%) reported discomfort at the 1-day postoperative visit; the therapeutic contact lens was retained in these patients. Thus, a number of patients in this study were continued with a therapeutic contact lens for a total time similar to that of standard CXL with epithelial removal.

### Comparison of Transepithelial Crosslinking to Standard Crosslinking

One of the major debates in keratoconus management is the relative efficacy of transepithelial CXL to the standard procedure. Therefore, although not directly comparable because of study design and entry criteria, it is of interest to compare our transepithelial CXL results with our clinical results of standard CXL with removal of the epithelium. In our previous study of CXL outcomes,<sup>2</sup> maximum K flattened by 2.0 D after 1 year compared with 0.45 D in the current study, suggesting that the standard procedure is more efficacious. However, the study cohorts for these 2 studies have important differences. First, the previous study was restricted to patients with documented progression of keratoconus compared with the current study in which all

keratoconus patients could be entered. Second, the average maximum K value of the entry population in the current trial was 57.0 D, compared with 60.4 D in the previous study, a difference that might affect expected outcomes. In previous work,<sup>40</sup> we have shown that preoperative maximum K is independently associated with greater 1-year postoperative improvement in maximum K; that is, eyes with worse keratoconus tend to have a more robust topographic flattening response to CXL. These population discrepancies, therefore, might account for some of the outcomes differences between the 2 studies because, on average, eyes in this study had less severe keratoconus. However, maximum K did worsen by 2 or more diopters in only 1 (2%) of 49 eyes in the previous study compared with 4 (5%) of 82 eyes in the current transepithelial study, and it improved by 2 or more diopters in 17 (35%) of 49 eyes in the previous study compared with 11 (13%) of 82 eyes reported herein, suggesting that there is less efficacy with this transepithelial approach than with standard CXL. Similarly, there was no significant change in mean K in our study population compared with a decrease of approximately 1.0 D found in our previous trial of standard CXL.<sup>2</sup> This, similarly, might be attributable to a somewhat less robust effect from a transepithelial procedure. Also, the mean K, which is measured from the central cornea, is generally a flatter area because maximum K is typically eccentric in keratoconus<sup>41</sup>; reiterating our previous findings,<sup>40</sup> flatter corneas tend to have less of a flattening effect from CXL, so this could also contribute to the finding of no change in mean K in our study.

Clinical trials have directly compared transepithelial to standard CXL, typically finding more robust results in standard treatment groups. Soeters et al.<sup>42</sup> performed a randomized trial in 61 patients comparing a standard protocol with a transepithelial protocol. They found 1-year topography stability in the transepithelial group compared with significant flattening of 1.2 to 1.5 D in the standard group, but also noted that 23% in the transepithelial group showed progression of maximum K after 1 year, compared with no longer term progression in the standard group. In a randomized study comparing standard CXL with iontophoresis-assisted crosslinking, Bikbova and Bikbov<sup>43</sup> found better stabilization and regression of K values in the standard group. Of note, the average depth of the demarcation line was 292  $\mu$ m in the standard group compared with only 172  $\mu$ m in the transepithelial group. Rush and Rush,<sup>44</sup> in a randomized trial of standard versus transepithelial CXL using an enhanced riboflavin solution, found improvement of 1.52 D in the steep K reading in the standard group, compared with only 0.54 D in the transepithelial group. Çerman et al.<sup>45</sup> similarly found more improvement in maximum, flat, and steep K with standard as compared with transepithelial treatments.

In addition to ultimate outcomes differences, there is a difference in the time course of wound healing comparing the transepithelial technique to standard CXL with epithelial removal. In standard CXL, all 3 outcomes indicators (maximum K, CDVA, and UDVA) tend to worsen at 1 month, resolve to baseline at 3 months, and improve thereafter.<sup>2</sup> This

tempo reflects healing responses to standard CXL as evidenced by the natural history of crosslinking-associated stromal haze.<sup>16</sup> Both epithelial and stroma wound-healing mechanisms might account for this postoperative time course. The epithelial thickness profile in native keratoconus typically shows a doughnut pattern; the epithelium is attenuated over the cone apex and thickened paracentrally.<sup>46,47</sup> Thus, the epithelium tends to mask and mitigate the stromal cone of keratoconus. With corneal deepithelialization in the standard CXL procedure, the more profound stromal irregularity is revealed, with an increase in measured maximum K. As the epithelium heals and remodels, topography improvement is seen. Stromal healing, too, might play a part in the time course of outcomes in the standard CXL procedure. In vitro and ex vivo studies have shown that standard CXL leads to an almost immediate loss of keratocytes in the corneal stroma.<sup>48</sup> Confocal microscopy in patients with keratoconus shows that activated keratocytes repopulate the corneal stroma starting at 2 months and stromal repopulation is almost complete at 6 months.<sup>49</sup>

As seen in our study of transepithelial CXL, the standard post-CXL time course showing worsening of outcomes at 1 month is not seen. This is a clinically advantageous finding. Likely, it is related to the retention of the epithelial layer, with a much-diminished epithelial healing response; it may also reflect altered stromal responses because epithelial removal might also militate stromal healing reactions. Therefore, whereas the purported advantages of transepithelial CXL include quick recovery and the general lack of a stromal haze response, it remains unclear whether the biological and wound-healing reactions signaled by the formation of stromal haze are actually unwanted or are, indeed, beneficial to the clinical topographic and disease stabilization effect of the CXL procedure.

We also looked at riboflavin dosing regimens during the UVA portion of the treatment: either every 1-minute or every 2-minute riboflavin administration during the 30-minute UVA administration. There are potentially conflicting advantages and disadvantages to greater or lesser riboflavin dosing during UVA administration. More frequent dosing might retain a higher riboflavin concentration in the cornea and thus facilitate more robust crosslinking. Conversely, the surface riboflavin film and the riboflavin within the epithelium might partially mask the incoming UVA and dissipate the power transmitted to the stroma, mitigating the crosslinking reaction.<sup>29</sup>

When directly comparing the 2 treatments, statistical analysis showed no significant differences in the changes in maximum K or mean K values, CDVA, or UDVA between eyes randomized to riboflavin administration either every 1 or 2 minutes. However, in within-group analyses, only the 1-minute cohort showed statistically significant improvement in maximum K. The 1-minute group improved by  $-0.73$  D, compared with the 2-minute cohort which improved by only  $-0.14$  D. Regarding this finding, it should be noted that there was a significant difference in preoperative mean maximum K between groups; the 1-minute group, preoperatively, was significantly less steep (55.2 D)

than the 2-minute group (59.2 D). Again, in previous work, we have shown that steeper corneas tend to flatten more robustly with crosslinking.<sup>40</sup> Thus, based on this, the 2-minute subgroup would have been expected to have a more substantial topography change simply based on the steeper preoperative maximum K. That the converse outcome was found supports our finding that the more frequent dosing regimen leads to more robust results. Although this certainly is not a dispositive finding with regard to riboflavin dosing in the transepithelial technique, it does belie the suggestion that rinsing the surface of riboflavin and adding no more riboflavin during the UVA phase will improve outcomes by diminishing epithelial screening of the incoming UVA power.<sup>30</sup> Further evaluation on this front is warranted before any clinical conclusions can be drawn.

A limitation of this study is the lack of a control group or treatment group with epithelial removal. Further controlled clinical trials evaluating different transepithelial protocols are essential to optimize the procedure. Variables such as riboflavin formulation, dosing regimen (including the option of adding no additional riboflavin during UVA administration), UVA power and time of administration, and oxygen availability might affect the outcomes of the transepithelial procedure. Moreover, when interpreting our results, it is important to note that inclusion criteria for this study admitted all keratoconic patients; although patients were chosen in whom CXL was felt to be indicated (ie, those patients with documented progression or at risk for progression), actual documentation of progression was not within the inclusion criteria. Because we had found in our previous work that patients with steeper corneas have a greater likelihood of topography improvement, study criteria did not exclude patients without documented progression in whom the likelihood of clinically significant topography improvement suggested a treatment benefit. Also, given the long-term nature of keratoconus progression, follow-up studies of greater than 1 year are essential in assessing the ultimate efficacy of this procedure, in particular because some studies of transepithelial CXL have shown loss of effect over time.<sup>42</sup> And, importantly, further controlled trials comparing the transepithelial protocol with the standard approach with epithelial removal are necessary to determine the relative risks and benefits of each.

#### WHAT WAS KNOWN

- Standard CXL with epithelial removal is safe and effective in decreasing maximum K in keratoconus and corneal ectasia.
- Results of transepithelial CXL have been mixed.

#### WHAT THIS PAPER ADDS

- There was statistically significant flattening of the cornea after transepithelial CXL, but less than that generally reported for standard CXL.
- The mean CDVA improved 1 year after transepithelial CXL.
- More frequent riboflavin dosing might improve outcomes.
- Longer term follow-up and controlled trials of transepithelial CXL using different protocols are necessary to optimize efficacy of the procedure.



## REFERENCES

- Wollensak G, Spoerl E, Seiler T. Riboflavin/ultraviolet-A-induced collagen crosslinking for the treatment of keratoconus. *Am J Ophthalmol* 2003; 135:620–627. Available at: [http://iofen.fi/files/2011/10/Wollensak\\_et\\_al\\_Keratoconus\\_2003.pdf](http://iofen.fi/files/2011/10/Wollensak_et_al_Keratoconus_2003.pdf). Accessed January 25, 2018
- Hersh PS, Greenstein SA, Fry KL. Corneal collagen crosslinking for keratoconus and corneal ectasia: one-year results. *J Cataract Refract Surg* 2011; 37:149–160. Available at: <http://www.vision-institute.com/UserFiles/File/CXL%20results%20published2011.pdf>. Accessed January 25, 2018
- Vinciguerra P, Albè E, Trazza S, Rosetta P, Vinciguerra R, Seiler T, Epstein D. Refractive, topographic, tomographic, and aberrometric analysis of keratoconic eyes undergoing corneal cross-linking. *Ophthalmology* 2009; 116:369–378
- Caporossi A, Mazzotta C, Baiocchi S, Caporossi T. Long-term results of riboflavin ultraviolet A corneal collagen cross-linking for keratoconus in Italy: the Siena Eye Cross Study. *Am J Ophthalmol* 2010; 149:585–593
- Raiskup-Wolf F, Hoyer A, Spoerl E, Pillunat LE. Collagen crosslinking with riboflavin and ultraviolet-A light in keratoconus: long-term results. *J Cataract Refract Surg* 2008; 34:796–801
- Greenstein SA, Fry KL, Hersh PS. Corneal topography indices after corneal collagen crosslinking for keratoconus and corneal ectasia: one year results. *J Cataract Refract Surg* 2011; 37:1282–1290
- Wittig-Silva C, Whiting M, Lamoureux E, Lindsay RG, Sullivan LJ, Snibson GR. A randomized controlled trial of corneal collagen cross-linking in progressive keratoconus: preliminary results. *J Refract Surg* 2008; 24:S720–S725
- Greenstein SA, Fry KL, Hersh MJ, Hersh PS. Higher-order aberrations after corneal collagen crosslinking for keratoconus and corneal ectasia. *J Cataract Refract Surg* 2012; 38:292–302
- Brooks NO, Greenstein S, Fry KL, Hersh PS. Patient subjective visual function after corneal collagen crosslinking for keratoconus and corneal ectasia. *J Cataract Refract Surg* 2012; 38:615–619
- Hersh PS, Stulting RD, Muller D, Durrie DS, Rajpal RK, on behalf of the United States Crosslinking Study Group. United States multicenter clinical trial of corneal collagen crosslinking for keratoconus treatment. *Ophthalmology* 2017; 124:1259–1270. Available at: <http://www.vision-institute.com/UserFiles/U.S.%20multicenter%20clinical%20trial%20of%20corneal%20collagen%20crosslinking%20for%20keratoconus%20treatment.pdf>. Accessed January 25, 2018
- Lesniak SP, Hersh PS. Transepithelial corneal collagen crosslinking for keratoconus: six-month results. *J Cataract Refract Surg* 2014; 40:1971–1979
- Rabinowitz YS. Keratoconus. *Surv Ophthalmol* 1998; 42:297–319. Available at: <http://www.keratoconus.com/resources/Major+Review+Keratoconus.pdf>. Accessed January 25, 2018
- Wollensak G, Iomdina E. Biomechanical and histological changes after corneal crosslinking with and without epithelial debridement. *J Cataract Refract Surg* 2009; 35:540–546
- Caporossi A, Mazzotta C, Baiocchi S, Caporossi T, Paradiso AL. Transepithelial corneal collagen crosslinking for keratoconus: qualitative investigation by in vivo HRT II confocal analysis. *Eur J Ophthalmol* 2012; 22 (suppl 7):S81–S88. Available at: <http://journals.sagepub.com/doi/pdf/10.5301/ejo.5000125>. Accessed January 25, 2018
- Hayes S, O'Brart DP, Lamdin LS, Douth J, Samaras K, Marshall J, Meek KM. Effect of complete epithelial debridement before riboflavin-ultraviolet-A corneal collagen crosslinking therapy. *J Cataract Refract Surg* 2008; 34:657–661
- Greenstein SA, Fry KL, Bhatt J, Hersh PS. Natural history of corneal haze after collagen crosslinking for keratoconus and corneal ectasia: Scheimpflug and biomicroscopic analysis. *J Cataract Refract Surg* 2010; 36:2105–2114. Available at: <http://www.vision-institute.com/UserFiles/File/CXL%20Haze%20Published.pdf>. Accessed January 25, 2018
- Rosenblatt E, Hersh PS. Intraoperative corneal thickness change and clinical outcomes after corneal collagen crosslinking: standard crosslinking versus hypotonic riboflavin. *J Cataract Refract Surg* 2016; 42:596–605
- Baiocchi S, Mazzotta C, Cerretani C, Caporossi T, Caporossi A. Corneal crosslinking: riboflavin concentration in corneal stroma exposed with and without epithelium. *J Cataract Refract Surg* 2009; 35:893–899
- Meadows DL, Paugh JR, Joshi A, Mordaunt J. A novel method to evaluate residence time in humans using a nonpenetrating fluorescent tracer. *Invest Ophthalmol Vis Sci* 2002; 43:1032–1039. Available at: <http://iovs.arvojournals.org/article.aspx?articleid=2200154>. Accessed January 25, 2018
- Stojanovic A, Chen X, Jin N, Zhang T, Stojanovic F, Raeder S, Utheim TP. Safety and efficacy of epithelium-on corneal collagen cross-linking using a multifactorial approach to achieve proper stromal riboflavin saturation. *J Ophthalmol* 2012; Article ID:498435. Available at: <http://www.ncbi.nlm.nih.gov/pmc/articles/PMC3413959/pdf/JOP2012-498435.pdf>. Accessed January 25, 2018
- McCarey B, Edelhauser H. In vivo corneal epithelial permeability following treatment with prostaglandin analogs with or without benzalkonium chloride. *J Ocul Pharmacol Ther* 2007; 23:445–451
- Kaur IP, Smitha R. Penetration enhancers and ocular bio-adhesives: two new avenues for ophthalmic drug delivery. *Drug Dev Ind Pharm* 2002; 28:353–369
- Ramselaar JAM, Boot JP, van Haeringen NJ, van Best JA, Oosterhuis JA. Corneal epithelial permeability after instillation of ophthalmic solutions containing local anaesthetics and preservatives. *Curr Eye Res* 1988; 7:947–950
- Kissner A, Spoerl E, Jung R, Spekl K, Pillunat LE, Raiskup F. Pharmacological modification of the epithelial permeability by benzalkonium chloride in UVA/riboflavin corneal collagen cross-linking. *Curr Eye Res* 2010; 35:715–721
- Caporossi A, Mazzotta C, Paradiso AL, Baiocchi S, Marigliani D, Caporossi T. Transepithelial corneal collagen crosslinking for progressive keratoconus: 24-month clinical results. *J Cataract Refract Surg* 2013; 39:1157–1163
- Filippello M, Stagni E, O'Brart D. Transepithelial corneal collagen crosslinking: bilateral study. *J Cataract Refract Surg* 2012; 38:283–291; erratum, 1515
- Lombardo M, Serrao S, Rosati M, Ducoli P, Lombardo G. Biomechanical changes in the human cornea after transepithelial corneal crosslinking using iontophoresis. *J Cataract Refract Surg* 2014; 40:1706–1715
- Mastropasqua L, Nubile M, Calienno R, Mattei PA, Pedrotti E, Salgari N, Mastropasqua R, Lanzini M. Corneal cross-linking: intrastromal riboflavin concentration in iontophoresis-assisted imbibition versus traditional and transepithelial techniques. *Am J Ophthalmol* 2014; 157:623–630
- Wollensak G, Aurich H, Wirbelauer C, Sel S. Significance of the riboflavin film in corneal collagen crosslinking. *J Cataract Refract Surg* 2010; 36:114–120
- Stojanovic A, Zhou W, Utheim PT. Corneal collagen cross-linking with and without epithelial removal: A contralateral study with 0.5% hypotonic riboflavin solution. *Biomed Res Int* 2014; article ID:619398. Available at: <https://www.ncbi.nlm.nih.gov/pmc/articles/PMC4090564/pdf/BMRI2014-619398.pdf>. Accessed January 25, 2018
- Kamaev P, Friedman MD, Sherr E, Muller D. Photochemical kinetics of corneal cross-linking with riboflavin. *Invest Ophthalmol Vis Sci* 2012; 53:2360–2367. Available at: <http://iovs.arvojournals.org/article.aspx?articleid=2188913>. Accessed January 25, 2018
- Zhang X, Sun L, Shen Y, Tian M, Zhao J, Zhao Y, Li M, Xhou X. Biomechanical and histopathologic effects of pulsed-light accelerated epithelium-on/off corneal collagen cross-linking. *Cornea* 2017; 36:854–859
- Seiler T, Hafezi F. Corneal cross-linking-induced stromal demarcation line. *Cornea* 2006; 25:1057–1059
- Mazzotta C, Balestrazzi A, Baiocchi S, Traversi C, Caporossi A. Stromal haze after combined riboflavin-UVA corneal collagen cross-linking in keratoconus: in vivo confocal microscopic evaluation [letter]. *Clin Exp Ophthalmol* 2007; 35:580–582
- Gatzioufas Z, Raiskup F, O'Brart D, Spoerl E, Panos GD, Hafezi F. Transepithelial corneal cross-linking using an enhanced riboflavin solution. *J Refract Surg* 2016; 32:372–377
- Koppen C, Wouters K, Mathysen D, Rozema J, Tassignon M-J. Refractive and topographic results of benzalkonium chloride-assisted transepithelial crosslinking. *J Cataract Refract Surg* 2012; 38:1000–1005
- Salman AG. Transepithelial corneal collagen crosslinking for progressive keratoconus in a pediatric age group. *J Cataract Refract Surg* 2013; 39:1164–1170
- Leccisotti A, Islam T. Transepithelial corneal collagen cross-linking in keratoconus. *J Refract Surg* 2010; 26:942–948
- Rechichi M, Daya S, Scordia V, Meduri A, Scordia G. Epithelial-disruption collagen crosslinking for keratoconus: one-year results. *J Cataract Refract Surg* 2013; 39:1171–1178
- Greenstein SA, Hersh PS. Characteristics influencing outcomes of corneal collagen crosslinking for keratoconus and ectasia: implications for patient selection. *J Cataract Refract Surg* 2013; 39:1133–1140. Available at: <https://pdfs.semanticscholar.org/b70c/ad7728b026b66e915b99f1791bf082a20731.pdf>. Accessed January 25, 2018
- Greenstein SA, Fry KL, Hersh PS. Effect of topographic cone location on outcomes of corneal collagen cross-linking for keratoconus and corneal ectasia. *J Refract Surg* 2012; 28:397–405. Available at: <http://archive.communiconology.org/site/blog/userfiles/old/61/file/0-10498000-1340215639.pdf>. Accessed January 25, 2018
- Soeters N, Wisse RPL, Godefruij DA, Imhof SM, Tahzib NG. Transepithelial versus epithelium-off corneal cross-linking for the treatment of progressive keratoconus: a randomized controlled trial. *Am J Ophthalmol* 2015; 159:821–828.e3

43. Bikbova G, Bikbov M. Standard corneal collagen crosslinking versus trans-epithelial iontophoresis-assisted corneal crosslinking, 24 month follow-up: randomized control trial. *Acta Ophthalmol* 2016; 94:e600–e606. Available at: <https://www.ncbi.nlm.nih.gov/pmc/articles/PMC5111766/pdf/AOS-94-e600.pdf>. Accessed January 25, 2018
44. Rush SW, Rush RB. Epithelium-off versus transepithelial corneal collagen crosslinking for progressive corneal ectasia: a randomized and controlled trial. *Br J Ophthalmol* 2017; 101:503–508
45. Çerman E, Toker E, Ozarslan Ozcan D. Transepithelial versus epithelium-off crosslinking in adults with progressive keratoconus. *J Cataract Refract Surg* 2015; 41:1416–1425
46. Reinstein DZ, Gobbe M, Archer TJ, Silverman RH, Coleman DJ. Epithelial, stromal, and total corneal thickness in keratoconus: three-dimensional display with Artemis very-high frequency digital ultrasound. *J Refract Surg* 2010; 26:259–271. Available at: <http://www.ncbi.nlm.nih.gov/pmc/articles/PMC3655809/pdf/nihms211821.pdf>. Accessed January 25, 2018
47. Rocha KM, Perez-Straziota CE, Stulting RD, Randleman JB. SD-OCT analysis of regional epithelial thickness profiles in keratoconus, postoperative corneal ectasia, and normal eyes. *J Refract Surg* 2013; 29:173–179; erratum, 234. Article available at: Available at: <http://m1.wyanokecdn.com/04008beb1db87e007e25f657e1766bcb.pdf>. Erratum available at: <https://www.healio.com/ophthalmology/journals/jrs/2013-4-29-4/%7B58bd59ec-9cf4-4583-9166-a43ec415bfe9%7D/erratum>. Accessed January 25, 2018.
48. Wollensak G, Spoerl E, Wilsch M, Seiler T. Keratocyte apoptosis after corneal collagen cross-linking using riboflavin/UVA treatment. *Cornea* 2004; 23:43–49
49. Mazzotta C, Traversi C, Baiocchi S, Caporossi O, Bovone C, Sparano MC, Balestrazzi A, Caporossi A. Corneal healing after riboflavin ultraviolet-A collagen cross-linking determined by confocal laser scanning microscopy in vivo: Early and late modifications. *Am J Ophthalmol* 2008; 146:527–533

#### OTHER CITED MATERIAL

- A. U.S. National Institutes of Health Clinical Trials. Transepithelial Corneal Collagen Crosslinking for Keratoconus and Corneal Ectasia. NCT01464268. Available at: <http://www.clinicaltrials.gov/ct2/show/NCT01464268?term=01464268&rank=1>. Accessed January 25, 2018

**Disclosures:** *None of the authors has a financial or proprietary interest in any material or method mentioned.*



#### First author:

Peter S. Hersh, MD

*Cornea and Laser Eye Institute–Hersh Vision Group, CLEI Center for Keratoconus, Teaneck, New Jersey, USA*